

Since the introduction of the surgical microscope, the act of locating and treating the MB2 in maxillary molars is no longer considered extraordinary. However, the mid-mesial canal of mandibular molars has not garnered as much attention. Approximately 14% of all mandibular first molars have a third mesial canal. This newsletter highlights two clinical examples of a mid-mesial canal in mandibular molars:

- 21 year-old healthy male; tooth No. 46 has irreversible pulpitis secondary to caries (fig 1a). Six orifices (fig 1b) were located on the floor of the chamber. A distinct mid-mesial canal is apparent in the post-op radiograph (fig 1c).
- 27 year-old healthy female; despite previous root canal treatment tooth No. 46 has a persistent buccal sinus tract. A diffuse radiolucent lesion is associated with the mesial root (fig 2a). The previous root canal treatment appeared adequate with four canals instrumented and filled to the radiographic apices. However, during retreatment, a previously untreated mid-mesial canal was located (fig 2b). All five canals were instrumented and medicated until the sinus tract healed. The third mesial canal is apparent on the post-op radiograph (fig 2c).

The mid-mesial canal is in the isthmus between MB and ML canal orifices. Failure to explore and clean the isthmus may result in a persistent intracanal infection. Careful observation of angled pre-op radiographs and use of a surgical microscope during treatment enhances the likelihood of locating the mid-mesial canal.

The second case could have easily been misdiagnosed as a vertical root fracture; extraction of this tooth would have been a true shame. A third mesial canal may be the source of poor healing of what initially appears to be adequate root canal treatment. Search for the mid-mesial canal whenever treating mandibular molars.

Please check our web page, Facebook page, and the BCDA blog for an electronic version of this newsletter. If you prefer, an e-mail version of this newsletter can be sent as well. I look forward to working with you and your patients in the future.

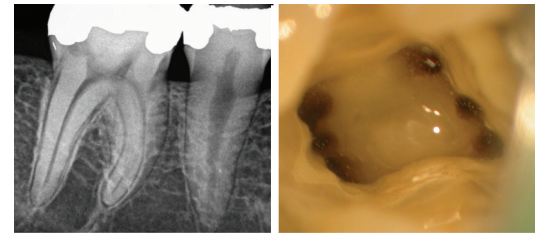
Regards,



Dr. Joel N. Fransen
BSc(OT), DMD, FRCD(C)
Certified Specialist in Endodontics

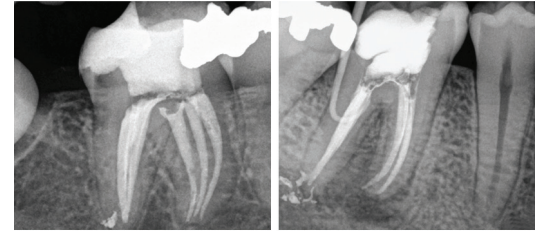


Lest We Forget



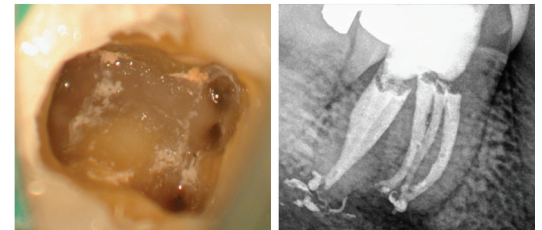
1a: PRE OP

1b: 6 Canal Orifices



1c: POST-OP

2a: PRE OP



2b: MID-MESIAL CANAL

2c: POST-OP



Thank you to all of those that attended our Hallowe'en Soiree!



Richmond Endodontic Centre
Dr. Joel N. Fransen

110-11300 No.5 Rd
Richmond, BC V7A 5J7
office@endodonticcentre.com
T 604.274.3499
F 604.274.3477

Office Hours

8am to 5pm - Monday to Saturday
Extended hours are also available

This newsletter and all of the previous newsletters are posted on our Facebook page 'RICHMOND ENDODONTIC CENTRE' and will be available on the updated web page (coming soon) at www.endodonticcentre.com.

If you have any questions about this or other newsletters please contact our office.