

Maxillary molars can be difficult to access efficiently. Figure 1 is of a tilted tooth; note the divergent angle of the crown and roots. The access did not compensate for this and the mesial wall was perforated. Prior to initiating an access, evaluate both a bitewing and at least two angle periapical radiographs.

The law of centrality states the pulp chamber is at the centre of the tooth at the level of the CEJ. This is only valid at the level of the CEJ; both the occlusal anatomy and angulation of the roots are independent of the CEJ.

A full coverage crown or large restoration can mask off-angle roots. Use a probe to evaluate the shape of the tooth at the level of the CEJ to confirm the relationship between the CEJ and the clinical crown. Both the clinical and radiographic evaluations are necessary to determine an effective access outline and proper angulations.

Figure 2 demonstrates the difference between a typical access for an upright molar and a corrected access for a tilted molar.

Figures 3 and 4 are of a root canal I recently completed. The tooth is not tilted but slightly rotated; so the access outline is centred more to the mesial. Often access preparations do not extend far enough palatally from the MB1 orifice to allow location the MB2 orifice. Clinically I am able to view both the palatal and DB orifices by slightly adjusting the angle of my mirror. Straight line access was achieved for all four canals, so the access did not require enlarging further. If I had trouble locating or negotiating a canal it would be prudent to enlarge the occlusal access. A small access preparation should not compromise your ability to locate canals and instrument them to length.

A small access in the right position can be enlarged as needed and will compliment the final outcome of the endodontic treatment. Please contact me if you have any questions about this or previous newsletters.

Regards,

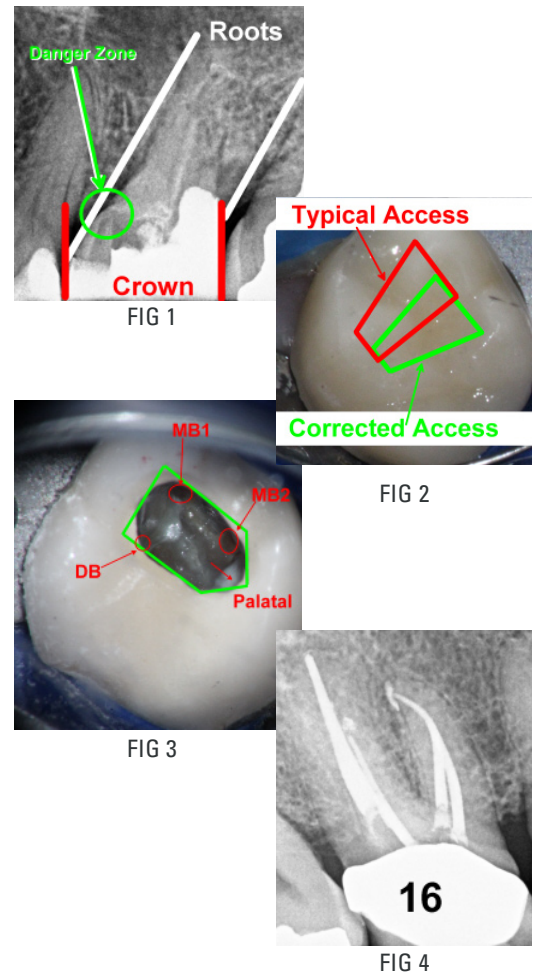


Dr. Joel N. Fransen  
BSc(OT), DMD, FRCD(C)  
Certified Specialist in Endodontics



This June I am riding with the team **Better Outcomes** to raise money for oral cancer research. Please consider helping me raise more money and thank you to all of those that have already donated.

Visit: [www.conquercancer.ca/goto/joelfransen2012](http://www.conquercancer.ca/goto/joelfransen2012)



**Richmond Endodontic Centre**  
Dr. Joel N. Fransen

**110-11300 No.5 Rd**  
Richmond, BC V7A 5J7  
office@endodonticcentre.com  
T 604.274.3499  
F 604.274.3477

**Office Hours**  
8am to 5pm - Monday to Saturday  
Extended hours are also available

This newsletter and all of the previous newsletters are posted on our Facebook page 'RICHMOND ENDODONTIC CENTRE' and will be available on the updated web page (coming soon) at [www.endodonticcentre.com](http://www.endodonticcentre.com) and the BCDA Discussion Forum Blog.

If you have any questions about this or other newsletters please contact our office.