



This newsletter reviews a case I was involved in four years ago. The patient was a 51 year-old lady who had a swelling buccal to tooth No. 45. It developed spontaneously with only mild sensitivity. Her dentist prescribed Amoxicillin and referred her for an evaluation. A review of her medical history revealed high blood pressure and type II diabetes; both controlled with diet and exercise. The patient was between 'bouts' of chemotherapy for uterine leiomyosarcoma that had metastasised to the liver.

No swelling or soft tissue abnormalities were noted. The area buccal to the 44 apex was tender to palpation and tooth No. 45 was necrotic (cold test and EPT). There was no percussion sensitivity and all other teeth in quadrant IV responded as expected. Radiographically, the unusual lesion was centred between the apices of teeth 44 and 45 and resorption was evident.

A diagnostic surgery and biopsy were performed. The pathology report revealed the lesion was metastatic leiomyosarcoma. Unfortunately the cancer progressed and the patient died within 18 months.

A few important points:

- A thorough review of each patient's medical history is critical
- Pathology can be present despite a lack of soft tissue abnormalities
- Radiographs are vital for a proper diagnosis
- Biopsies should be performed on soft tissue lesions
- Non-restored teeth that are necrotic and/or have a lesion are a distinct concern

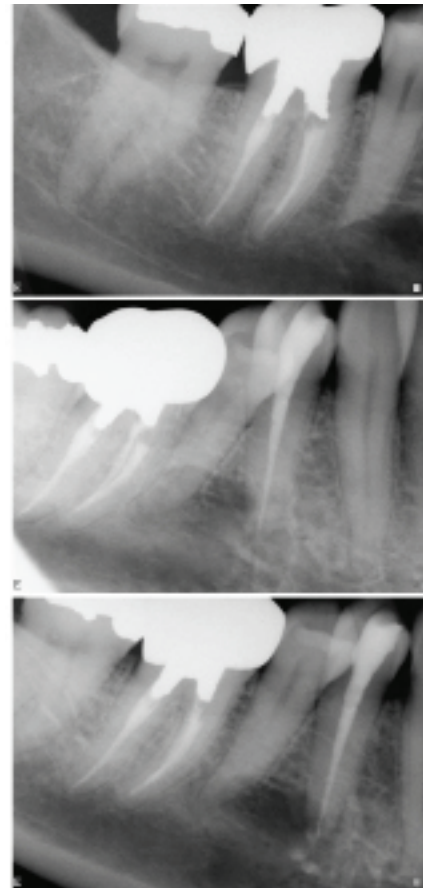
The intent of this newsletter is to encourage both you and your team to remain diligent in protecting the health of your patients. A referral to the Richmond Endodontic Centre is worthwhile if you are unsure of a diagnosis.

Please review the Richmond Endodontic Centre Facebook page for more details. I welcome your comments, questions, and suggestions about this and previous newsletters.

Regards,



Dr. Joel N. Fransen  
BSc(OT), DMD, FRCD(C)  
Certified Specialist in Endodontics



**Richmond Endodontic Centre**  
Dr. Joel N. Fransen

**110-11300 No.5 Rd**  
Richmond, BC V7A 5J7  
office@endodonticcentre.com  
T 604.274.3499  
F 604.274.3477

**Office Hours**

8am to 5pm - Monday to Saturday  
Extended hours are also available

This newsletter and all of the previous newsletters are posted on our Facebook page 'RICHMOND ENDODONTIC CENTRE' and will be available on the updated web page (coming soon) at [www.endodonticcentre.com](http://www.endodonticcentre.com).

If you have any questions about this or other newsletters please contact our office.