

This month is an update of the October'11 newsletter. There are three sources for old newsletters: www.endodonticcentre.com, the Richmond Endodontic Facebook page, or ringing/e-mailing our office.

Immature permanent teeth have roots that are short and thin with blunderbuss apices; treatment via RCT is fraught with difficulties and the long-term prognosis is poor without microsurgery. Regenerative endodontics fosters development of root length and wall thickness; it is superior to apexification via calcium hydroxide, calcium silicate (Biodentine), or MTA. All necrotic immature permanent teeth are candidates for treatment. The best results for regenerative endodontics are for those 8 to 18 years old with large blunderbuss apices.

The images to the right are of a premolar with a necrotic pulp secondary to dens invaginatus. It was successfully treated via regenerative endodontics.

Informed consent is important as randomised controlled clinical trials do not exist for regenerative endodontics. Recommendations for the two phases of treatment are:

First Phase

- Determine working length but do not instrument the canal walls
- Disinfect via irrigation not instrumentation, deliver irrigants slowly to apical portion of canal but not beyond the apex
- Dry with sterile paper points, then medicate with tri-antibiotic paste (can cause staining)

Second Phase

- Only use adrenaline-free local anaesthetic
- Remove the antibiotic paste and gently irrigate
- EDTA should be the last irrigant, then dry canal with sterile paper points
- Then promote bleeding back into the canal

The best matrix is a newly formed blood clot. However, Colla-Plug is often used as it allows for better control of the positioning of the MTA or Biodentine. Platelet-rich plasma (PRP) has great potential as a resorbable matrix since it is autologous, relatively easy to prepare, rich with growth factors, degrades over time, and forms a 3-D fibrin matrix.

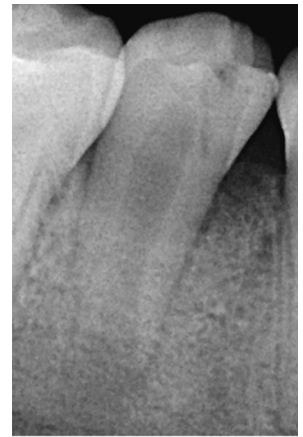
Regenerative endodontic treatment is one of the many services provided at the Richmond Endodontic Centre. In addition, nitrous oxide sedation is also available to help those that may be apprehensive. Please consider my office when looking for modern endodontic solutions.

Regards,

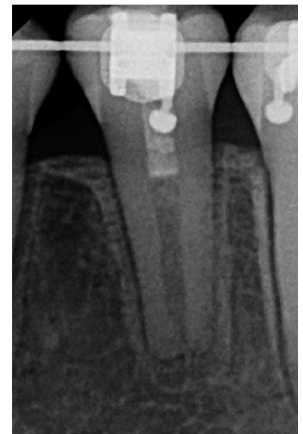

Dr. Joel N. Fransen
BSc(OT), DMD, FRCD(C)
Certified Specialist in Endodontics

PRE-OP



3 YEAR RECALL



Richmond Endodontic Centre
Dr. Joel N. Fransen

110-11300 No.5 Rd
Richmond, BC V7A 5J7
office@endodonticcentre.com
T 604.274.3499
F 604.274.3477

Office Hours

8am to 5pm - Monday to Friday
Extended hours are also available

Thank you to all those that donated to the Better Outcomes team. We raised over \$55,000.00 for oral cancer research.

