

This month's newsletter addresses cracked teeth. With the World Cup upon us, the HST on the horizon, and a year of financial ups and downs it seemed an apt topic to discuss. Patients with cracked teeth present with a variety of symptoms. Some describe a tooth sensitive to cold and that is a 10/10 on the pain scale. These teeth often have a serviceable restoration and no caries or pathology evident on the radiograph. However, they do have an irreversible pulpitis that is in need of definitive treatment. At other times, cracked teeth present with radiographic pathology but are asymptomatic. Diagnosing cracked teeth and relating the crack to long-term prognosis can be a challenge.

For an asymptomatic tooth with a visible crack but no radiographic pathosis, a crown is the treatment of choice. If a prophylactic root canal is not performed it is advisable to keep the tooth in a temporary for a month to ensure no symptoms develop.

The extent of the crack will affect the prognosis of the tooth. For that reason, it is often necessary to access the tooth to determine the extent of the crack. A crack that terminates in the coronal 1/3 of the crown has a reasonably good prognosis. However, a tooth that has a crack that dives down the canal system has a poor prognosis. It is important to utilize magnification with co-axial light throughout endodontic therapy to determine which teeth have cracks and which do not.

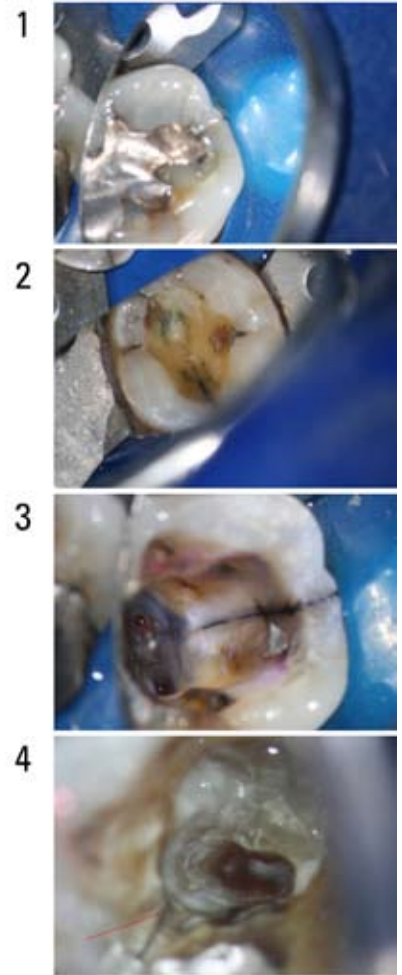
When the crack establishes a communication with the PDL it can cause periodontal attachment loss. This is often seen as a deep narrow probing defect. A tooth with a crack which has periodontal probing defect greater than 6mm has a hopeless prognosis. As a result, when a visible occlusal crack is found in correlation with a deep isolated probing defect accessing the tooth is an academic exercise. Extraction is unavoidable.

We look forward to becoming a long-term asset for your dental team. Our grand opening is on Wednesday the 30th of June (5-9pm). If you and your staff are interested in attending, please contact us to RSVP.

Regards,



Dr. Joel N. Fransen
BSc(OT), DMD, FRCD(C)
Certified Specialist in Endodontics



Richmond Endodontic Centre
Dr. Joel N. Fransen

110-11300 No.5 Rd
Richmond, BC V7A 5J7
office@endodonticcentre.com
T 604.274.3499
F 604.274.3477

Office Hours

8am to 5pm - Monday to Saturday
Extended hours are also available

This newsletter and all of the previous newsletters are posted on our Facebook page 'RICHMOND ENDODONTIC CENTRE' and will be available on the updated web page (coming soon) at www.endodonticcentre.com.

If you have any questions about this or other newsletters please contact our office.