

Access Cavity Perforations

These perforations are most often supracrestal with leakage of saliva into the access cavity or sodium hypochlorite into the mouth being common indicators. If the access cavity perforation extends to the PDL, bleeding will also be present.

Obtaining haemostasis is critical prior to repairing the perforation. If a dry field cannot be achieved, placement of Ca(OH)₂ or Diapex over the perforation for a few days will help with haemostasis as well as act as an anti-bacterial agent. It is important to inform the patient of the perforation and consider a referral to the Richmond Endodontic Centre.

Repair of an access cavity perforation should be done as soon as possible with the material providing an adequate seal without causing further tissue damage. Glass ionomers and composites (i.e. Geristore) are ideal for repairing supracrestal perforations. MTA (ProRoot) is not ideal for supracrestal perforation repairs as it may 'wash out' over time. An access cavity perforation that is not successfully repaired will communicate with the sulcus leading to periodontal complications.

Root Perforations

The location and size of a radicular perforation influences both the prognosis and the steps necessary for resolution. A small perforation (approx. 1x1mm) may be sealed from within the tooth, whereas surgery is often necessary to repair larger perforations.

Repair of root perforations is technically demanding and requires the high magnification of a digital operating microscope. If a root perforation is suspected, inform the patient and consider a referral to the Richmond Endodontic Centre. In the meantime, passively place calcium hydroxide or Diapex in the canal to act as a temporary barrier.

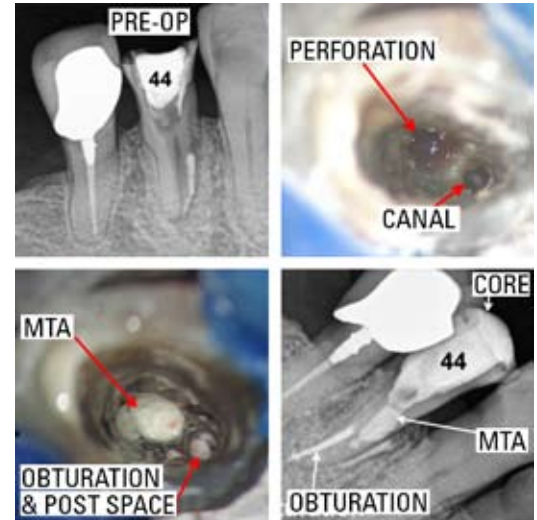
HELPFUL HINTS

1. A "check" radiograph with an endo file will help determine the location of the perforation
2. The sooner the perforation is repaired, the better the prognosis
3. Calcium hydroxide or Diapex are ideal interim treatment materials

Regards,



Dr. Joel N. Fransen
BSc(OT), DMD, FRCD(C)
Certified Specialist in Endodontics



CONGRATULATIONS
to the office of Dr. Inderjit Dulay for
winning the A-list Referral Prize for July!

CONGRATULATIONS
to Dr. Garrick Liang and Dr. Jennifer Yee
on their recent marriage!



Richmond Endodontic Centre
Dr. Joel N. Fransen

110-11300 No.5 Rd
Richmond, BC V7A 5J7
office@endodonticcentre.com
T 604.274.3499
F 604.274.3477

Office Hours
8am to 5pm - Monday to Saturday
Extended hours are also available

This newsletter and all of the previous newsletters are posted on our Facebook page 'RICHMOND ENDODONTIC CENTRE' and will be available on the updated web page (coming soon) at www.endodonticcentre.com.

If you have any questions about this or other newsletters please contact our office.