

> C-SHAPED CANALS,  
PROCEED WITH 'C'AUTION

FEB  
2012

Variations in the anatomy of a canal system can pose a significant challenge in achieving successful endodontic therapy. During development, a partial or complete merging of roots can lead to a C-shaped canal configuration. This anomaly can occur in any tooth but is most common in mandibular second molars. It is most common in Asians, least common in Caucasians, and always a possibility when a molar has fused roots.

Typically, mandibular molars have two roots and three canals. If this is not obvious, suspect a C-shaped canal configuration and be cognisant of its inherent challenges:

1. On the chamber floor, the 'C' often presents as a thin fin or web connecting mesial(s) and distal(s) orifices. However, the C-shape may present anywhere along the length of the root with no obvious clues on the chamber floor.
2. The dentinal walls are particularly thin on the inner aspect of the "C". Instrumentation techniques will need to be modified in order to avoid strip perforations and yet thorough enough to ensure optimum débridement and disinfection.
3. Complex intercommunications exist between the canals along the entire length of the root. A more thorough irrigation protocol will be necessary as well as modifications to the access preparation, instrumentation regimen, and obturation technique.

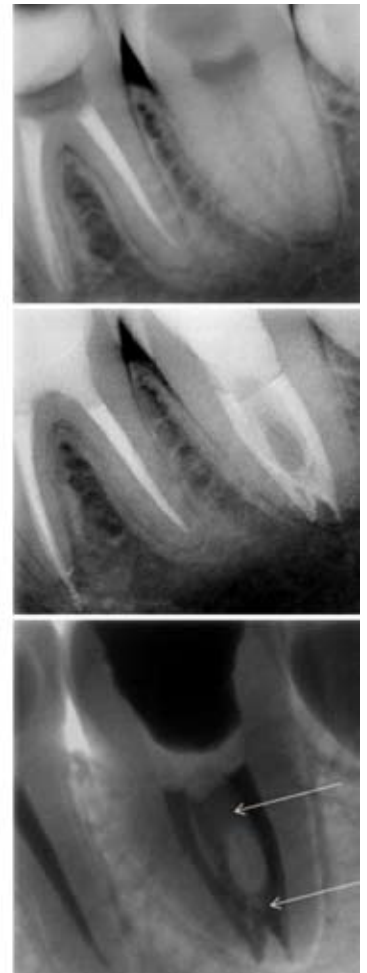
The surgical operating microscope and endodontic ultrasonic tips allow controlled access to the canal system. With proper access and modified endodontic techniques the prognosis for long-term success is excellent.

Please check our web page, Facebook page, Twitter updates, and the BCDA blog for an electronic version of this and previous newsletters. An e-mail version is also available upon request. If you ever have any questions or concerns, don't hesitate to contact me or stop by the office.

Regards,



Dr. Joel N. Fransen  
BSc(OT), DMD, FRCD(C)  
Certified Specialist in Endodontics



**Richmond Endodontic Centre**  
Dr. Joel N. Fransen

**110-11300 No.5 Rd**  
Richmond, BC V7A 5J7  
office@endodonticcentre.com  
T 604.274.3499  
F 604.274.3477

**Office Hours**  
8am to 5pm - Monday to Saturday  
Extended hours are also available

This newsletter and all of the previous newsletters are posted on our Facebook page 'RICHMOND ENDODONTIC CENTRE' and will be available on the updated web page (coming soon) at [www.endodonticcentre.com](http://www.endodonticcentre.com) and the BCDA Discussion Forum Blog.

If you have any questions about this or other newsletters please contact our office.