

Apicoectomy is the old term for endodontic microsurgery. Due to the 50+% increase in success rate over traditional apicoectomies the new term, endodontic microsurgery, was adopted. The increase in success can be attributed to many factors specific to surgery with a microscope:

1. Smaller osteotomy site
2. Resection of apical 3mm of root eliminates 98% of apical ramifications and 93% of lateral canals
3. A more horizontal resection
4. Increase visualisation of resected surfaces
5. 3mm retrofilling preparation along the long-axis the root
6. Use of MTA (Mineral Trioxide Aggregate), an osteo- and cemento-inductive material

Endodontic microsurgery is minimally invasive, does not interfere with the existing coronal restoration, or the health/aesthetics of the periodontium. The healing response is quick with little to no discomfort. Prior to making a recommendation, it is necessary to consider the pros and cons of non-surgical retreatment versus microsurgery.

The photographs and radiographs above are of a recent microsurgery performed by Dr. Fransen. A general dentist recently completed the root canal treatment and crown, with swelling and pain developing four weeks later.

Endodontic microsurgery was recommended for the following reasons:

1. Referring dentist performs modern asepsis endodontics
2. No evidence of coronal leakage
3. Complex apical anatomy, missed canal in apical third of root

During surgery, two canals were located with no obturation material in the palatal canal. The two canals unite 2mm coronal to the resection. MTA was used to seal the retro-preps. The patient experienced little to no post-op discomfort; the tooth is now asymptomatic and functional.

Endodontic microsurgery is an effective and successful procedure that eliminates periradicular pathosis, maintains the current restoration, and restores the function of the tooth. Please contact us with any questions about this newsletter or suggestions for future newsletters.


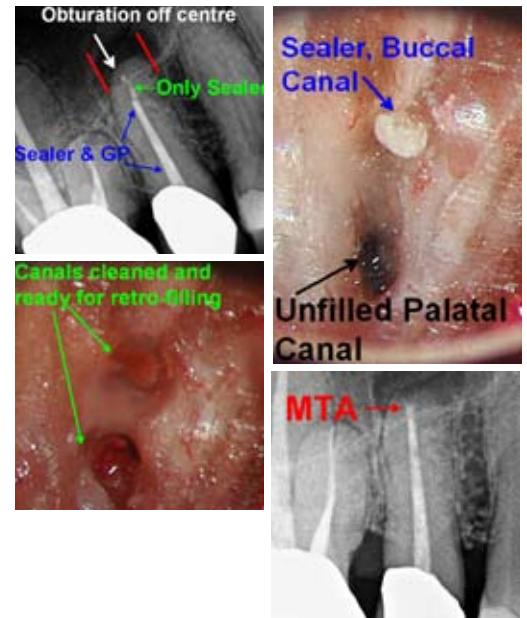
Regards,



Dr. Joel N. Fransen  
BSc(OT), DMD, FRCD(C)  
Certified Specialist in Endodontics



Dr. Garrick Liang  
BSc, DMD, FRCD(C)  
Certified Specialist in Endodontics



1<sup>ST</sup> YEAR  
ANNIVERSARY!



**Richmond Endodontic Centre**  
Dr. Joel N. Fransen  
Dr. Garrick Liang

**110-11300 No.5 Rd**  
Richmond, BC V7A 5J7  
office@endodonticcentre.com  
T 604.274.3499  
F 604.274.3477

**Office Hours**  
8am to 5pm - Monday to Saturday  
Extended hours are also available

This newsletter and all of the previous newsletters are posted on our Facebook page 'RICHMOND ENDODONTIC CENTRE' and will be available on the updated web page (coming soon) at [www.endodonticcentre.com](http://www.endodonticcentre.com).

If you have any questions about this or other newsletters please contact our office.