

Cotton Cores Contaminate Endodontic Treatment

A sponge or cotton pellet is often placed in the pulp chamber following endodontic treatment. With time, these materials become a haven for contaminants and can present, clinically, as an unexplained furcal radiolucency, -abscess, -recession, or a sinus tract that traces back to the furcation. A large void in the pulp chamber is often associated with the furcal radiolucency. Contamination of the pulp chamber stymies the prognosis for long-term retention of a tooth.

To avoid such a scenario the endodontists at the Richmond Endodontic Centre place flowable composite in the coronal portion of the canals and advise patients to have a permanent core restoration within a fortnight (2 weeks). The seal of the temporary restoration is reliable for thirty days; patients are discouraged from testing this limit. Prior to placing the core, remove the entire sponge and temporary restoration. Firmly abut the new core against the chamber floor and flowable composite in the orifices of the canals.

In Summary:

- The core filling should be placed within 30 days of the completion of endodontic treatment
- Always abut the new core against the flowable composite/endodontic material in the canal orifice
- Voids in the chamber are nidi of contamination

Fig 1 – A furcal radiolucency and void in the pulp chamber strongly suggest contaminants are present. Indeed the cotton core was contaminated and endodontic retreatment was necessary on an otherwise stable tooth.

Fig 2 – A radiolucency envelopes the mesial root and a void exists over the orifices. IRM appears to seal the distal orifice and no radiolucency is associated with the distal root. Although a 'j'-shaped is often pathognomonic for a vertical root fractures, none were present on this tooth. Instead, a contaminated cotton pellet was found under the core and retreatment was ultimately successful.

The Richmond Endodontic Centre is committed to excellence in endodontics working with you in providing top-notch endodontic care for your patients.

Regards,



Dr. Joel N. Fransen
BSc(OT), DMD, FRCD(C)
Certified Specialist in Endodontics

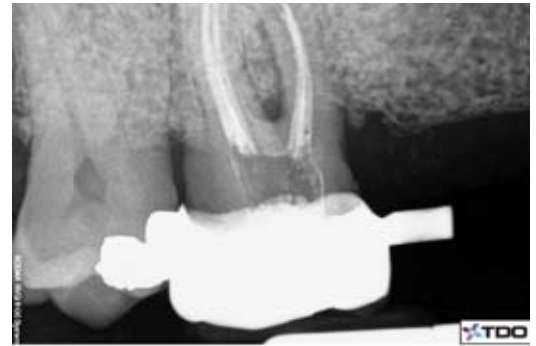


Fig 1

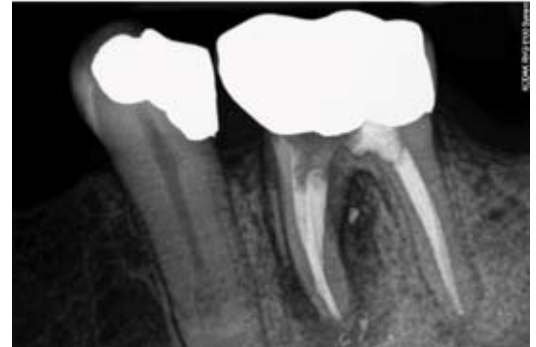


Fig 2

Congratulations to Dr. Calvin Chan for winning the A list referral prize for August and on his new edition to his family, a baby girl!!



Richmond Endodontic Centre
Dr. Joel N. Fransen

110-11300 No.5 Rd
Richmond, BC V7A 5J7
office@endodonticcentre.com
T 604.274.3499
F 604.274.3477

Office Hours

8am to 5pm - Monday to Saturday
Extended hours are also available

This newsletter and all of the previous newsletters are posted on our Facebook page 'RICHMOND ENDODONTIC CENTRE' and will be available on the updated web page (coming soon) at www.endodonticcentre.com and the BCDA Discussion Forum Blog.

If you have any questions about this or other newsletters please contact our office.