

Pre-Endodontic Build-Ups

Teeth requiring root canal treatment are often missing significant tooth structure from either caries or a prior restoration. In order to provide reliable isolation during the disinfection of the root canal system, a pre-endodontic build-up is placed. This build-up is also known as an asepsis restoration (BCDA fee code 39101). In Picture 1, a dual-cure glass ionomer (Fuji Triage) was used; it offers two distinct advantages:

1. It is durable and will provide a reliable seal for a few months.
2. It's pink colour is easily discernible from tooth structure.

When an aesthetic result is necessary, a white glass ionomer can be employed. These pre-endodontic build-ups should not be left as part of the permanent restoration as they exhibit poor compressive strength and long-term bonding.

The asepsis restoration can serve as an excellent matrix for the permanent core. Using a shoulder diamond bur, the asepsis filling can be thinned from the access cavity to make a custom matrix for the core (Picture 2). The glass ionomer 'matrix' must be removed during the crown preparation.

An exception to this rule is demonstrated in Pictures 3 to 4. In this case, a composite asepsis restoration was placed after caries excavation. This provided isolation and upon completion of the root canal treatment a composite core was placed. This allowed the referring dentist to proceed directly to a crown preparation.

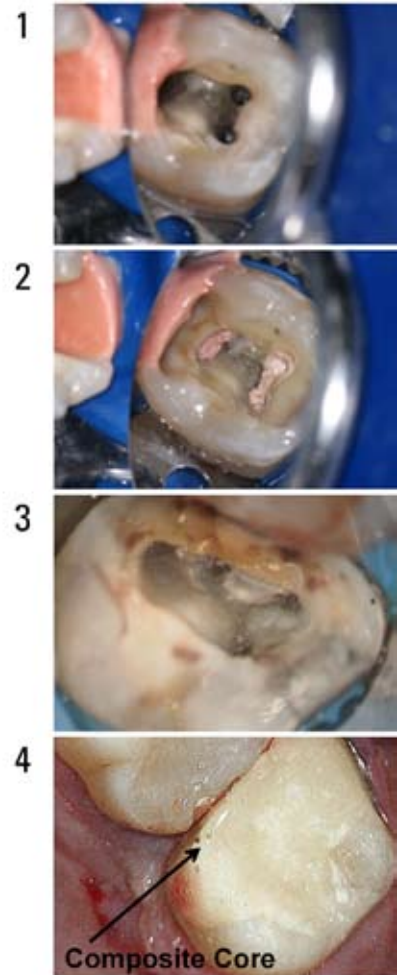
Most often, an orifice barrier such as PermaFlo Purple is bonded in the coronal portion of the canals. Other orifice barrier materials include resin, glass ionomer, amalgam, and various composites. If these materials are on the pulpal floor, they should be left in place. More information about orifice barriers is available in the November 2010 and January 2011 Newsletters. Please contact our office if you would like a reprint or e-mail of these or previous newsletters.

At the Richmond Endodontic Centre we work to compliment your restorative goals. I look forward to your comments, questions, and suggestions about this and previous newsletters. Thank you for the opportunity to be a part of your dental team!

Regards,



Dr. Joel N. Fransen
BSc(OT), DMD, FRCD(C)
Certified Specialist in Endodontics



Richmond Endodontic Centre
Dr. Joel N. Fransen

110-11300 No.5 Rd
Richmond, BC V7A 5J7
office@endodonticcentre.com
T 604.274.3499
F 604.274.3477

Office Hours
8am to 5pm - Monday to Saturday
Extended hours are also available

This newsletter and all of the previous newsletters are posted on our Facebook page 'RICHMOND ENDODONTIC CENTRE' and will be available on the updated web page (coming soon) at www.endodonticcentre.com.

If you have any questions about this or other newsletters please contact our office.