



An overfill (OF) is the extrusion of sealer, GP or other obturation materials, medicaments, irrigants, bacteria, instruments, paper points, posts, or other items beyond the apical constriction. Independent of the presence of bacteria, an OF causes mechanical and chemical irritation of the periapical tissue. At a minimum it will retard the healing process and at worst cause permanent damage to surrounding structures. Complications associated with OF can include: pain, swelling, active apical periodontitis, fascial space involvement, paraesthesia, dysaesthesia, anaesthesia, allodynia, vague aches, and sinus issues. Pain and nerve damage can arise immediately whilst a dull ache or aspergilliosis may develop months later with no betoken symptoms.

As a rule of thumb, the severity of the injury and immediacy of symptoms is not as strongly related to bacteria as it is to the composition of the OF, the amount extruded, and if direct damage to surrounding structures occurred. The risk of damage is heightened if the OF material is solid rather than liquid, non-resorbable, and not inert but an irritant or worse. If an egregious amount of material is extruded the prognosis can be grim even if the material is rather innocuous. Perforation of the maxillary sinus or direct impingement of the mandibular nerve are particularly unfavourable developments. Bacteria need not be present for an OF to cause severe and irreparable harm.

If the severity of the physical damage, be it from direct impact or impingement via indirect pressure (i.e. pronounced inflammatory and immune response), is not catastrophic the presence of bacteria is central to long-term success. Lower rates of healing are associated with OF cases that have the following characteristics:

- Necrotic pulp or retreatment, especially if a pre-op radiolucency is present
- Lack of apical constriction (i.e. immature or resorbed apices, over-instrumentation, apical transportation)
- OF material that is a 'safe harbour' for viable bacterial colonies

Early determination of the true aetiology (physical and/or bacterial) is paramount to damage limitation. The greater the physical insult of an OF the more likely the aetiology is solely mechanical. Immediate anti-inflammatory and analgesic use is crucial. The longer the inflammation persists the less plausible an atraumatic and full recovery becomes. Retreatments or surgery may be considered only if the OF can be removed with minimal risk of additional trauma. Frank pre-op evidence of bacterial activity favours an antibiotic prescription as well as a possible incision and drainage. Below is a rudimentary guide for OF cases:

- Two or more angled post-op radiographs
- Inform, re-assure, and closely monitor the patient
- Robust documentation
- Aggressive anti-inflammatory regimen with complimentary analgesics
- Possible antibiotic prescription
- Consider a referral for a second opinion and/or a CBCT evaluation

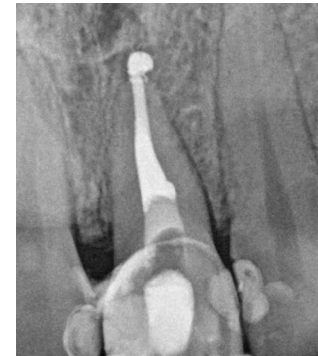
A thorough and forthright approach to an OF will mitigate mal issues for the patient and you. Most, but not all, OF events result in no short-term symptoms and the tooth remains stable for the long-term with little or no intervention. Invasive interventions such as retreatment, microsurgery, extraction, and the like are seldom warranted as the post-op damage can easily worsen the final outcome (aegrescit medendo).

There is little reason to get in huff about a small ZOE-based sealer puff for a 21 that had irreversible pulpitis. On the other hand, reach for an inhaler if the fourth canal obturated on the retreatment of an infected 46 is the inferior alveolar canal and an out-of-date glass ionomer sealer and metal carriers were used. Sometimes OF can stand for more than just overfill.

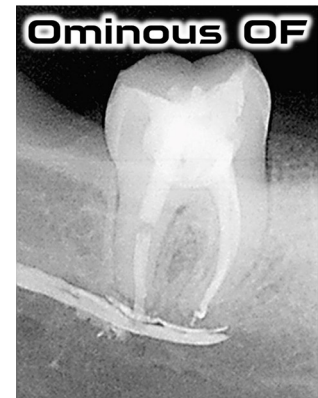
Regards,



Joel N. Fransen  
BSc(OT), DMD, FRCD(C)  
Certified Specialist in Endodontics



Pas de Problème



Ominous OF



Richmond Endodontic Centre  
Dr. Joel N. Fransen

110-11300 No.5 Rd  
Richmond, BC V7A 5J7  
office@endodonticcentre.com  
T 604.274.3499  
F 604.274.3477

Office Hours  
8am to 5pm - Monday to Friday  
Extended hours are also available

**I am dedicating the 2020 Ride to my grandmother Margaret Fransen who was taken by cancer when my dad was merely a lad.** Cancer stole my dad's mum from him but I will honour the positive impact she made on my dad and his two sisters.

Please consider donating to my 2020 Ride to Conquer Cancer.

