

Hippocrates: 'the art is long and life is short'. The art in question is medicine/ diagnosis and the short life is our career and to make what we can of it. This case is a diagnostic challenge that I could have easily failed. Recently, a 58 year-old healthy Caucasian was referred because his hygienist noticed a sinus tract palatal to the 16. The tooth is asymptomatic and the gentleman was previously oblivious to the presence of the sinus tract. Clinically, the 16 has a shallow amalgam and a few craze lines. In addition to these two findings, the conical root form increases my suspicion of a vertical root fracture and/ or pulp necrosis. No probing defects are present nor abnormal mobility. No tenderness to percussion, bite, chewing, or even palpation exists. Not unlike its neighbours the pulp of the 16 responds normally to cold and EPT. Radiographically the apical PDL is not widened and the sinus tract only traces to the apical third of the palatal root, not the apex.

Although obvious to me now, initially I did not identify the supernumerary tooth on the pre-operative PA's. Flummoxed at the lack of defendable diagnosis, I requested CBCT imaging to allow a more detailed evaluation of the 16 and surrounding hard tissue.

The cone beam CT images confirms the presence of a hard tissue mass palatal to the palatal root. My treatment recommendation is extraction of the defect with a biopsy of the hard and soft tissue. Despite advising the patient a lack of pain is not synonymous with an absence of pathology, he decided to forgo treatment, preferring to see if anything changes over time. I advised the patient the defect is a liability and there is no discernible benefit to inaction.

The most common type of supernumerary tooth is a mesiodens (i.e. near the midline) and it is typically diagnosed in childhood. The prevalence of supernumerary teeth in permanent dentition for Caucasians is between 0.1 to 3.5%. It is slightly more common in Asian and sub-Sahara populations. Thus, this case is an uncommon form of a relatively rare condition. A supernumerary tooth is the most likely, but indeed not the only hard tissue defect possibly responsible for the sinus tract. Arresting the infective process and confirming the diagnosis are the rationale for recommending extraction of the mass and a histopathological sampling. Below is a synopsis of a few salient points from this case:

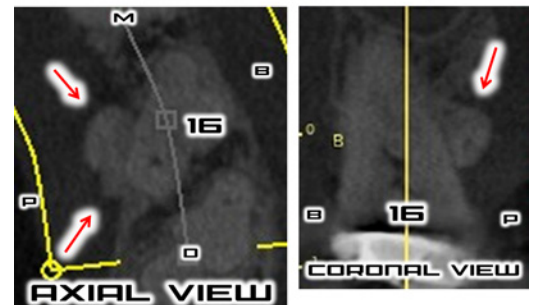
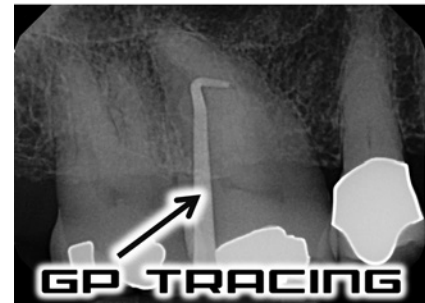
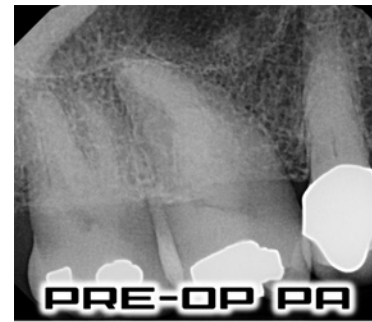- Always take two angled pre-op PA's for possible endo cases
- Always perform pulp and periradicular tests as well as a thorough clinical examination
- Periodontally probe all teeth under consideration for endodontic treatment
- Further investigation or a referral is warranted if the diagnosis remains ambiguous

I once heard: 'there are five reasons for referring a patient: to diagnose, to reassure, to manage, to cure, and to punish.' The fifth reason may not be to punish the patient but rather the unsuspecting clinician who has not embraced the art of diagnosis which can make for long work days indeed. It is cases like this that help all of us sharpen our clinical skills and shorten our work days, or at least it feels like that.

Regards,



Joel N. Fransen
BSc(OT), DMD, FRCD(C)
Certified Specialist in Endodontics



Richmond Endodontic Centre
Dr. Joel N. Fransen

110-11300 No.5 Rd
Richmond, BC V7A 5J7
office@endodonticcentre.com
T 604.274.3499
F 604.274.3477

Office Hours
8am to 5pm - Monday to Friday
Extended hours are also available

**Let's Take The Fight
Against Oral Cancer To
The Mountains!**

Please consider donating to my
2019 Ride to Conquer Cancer.

